ORIGINAL ARTICLE

Firearm injuries in pediatric surgery: Pediatric trauma center experiences

Elif Emel Erten,[1] Can İhsan Öztorun,[2] Ahmet Ertürk,[2] Süleyman Arif Bostancı,[1] Sabri Demir,[3] Vildan Selin Şahin,[1] Bekir Dinçer,[4] Sait Özsoy,[5] Müjdem Nur Azılı,[5] Emrah Şenel[5]

[1]Department of Pediatric Surgery, Ankara Bilkent City Hospital, Ankara-*Türkiye*
[2]Department of Pediatric Surgery, Ankara Yıldırım Beyazıt University Faculty of Medicine, Ankara-*Türkiye*
[3]Department of Pediatric Surgery, University of Health Sciences Faculty of Medicine, Ankara-*Türkiye*
[4]Ankara Regional Office, Council of Forensic Medicine, Ankara-*Türkiye*
[5]Department of Forensic Medicine,University of Health Sciences, Gülhane Faculty of Medicine, Ankara-*Türkiye*

ABSTRACT

BACKGROUND: This study aimed to evaluate the epidemiological data on thoracic and abdominal firearm injuries in children treated by pediatric surgeons at a pediatric trauma center.

METHODS: Children hospitalized with firearm injuries from 2015 to 2022 were retrospectively analyzed. Patient demographics, affected organs, treatment approaches, and length of hospital stay were examined.

RESULTS: The mean age of the patients was 12.43±2.31 years; 27 (84.4%) were male and five (15.6%) were female. Bullet injuries were associated with higher severity and often required major surgical intervention, whereas pellet injuries were generally managed conservatively. For thoracic injuries, conservative management was effective in stable cases without immediate life-threatening complications, while abdominal injuries more often required invasive surgical procedures. Notably, unintentional firearm injuries were more common in younger children, whereas intentional injuries were more prevalent among older adolescents. This age-related pattern revealed a statistically significant correlation between age and type of firearm injury (p=0.002). Additionally, the majority of patients with thoracic injuries underwent minor surgical procedures, whereas those with abdominal injuries primarily required major surgeries.

CONCLUSION: This study indicates that accidental firearm injuries are more common among younger age groups, while intentional firearm injuries tend to occur more frequently in older children.

Keywords: Trauma in children; firearm injuries; thoracic trauma; abdominal trauma.

INTRODUCTION

Firearm injuries (FIs) have a higher mortality rate (20%) compared to other traumatic mechanisms due to their high velocity, penetrating nature, and the potential for shock from intraperitoneal vascular extravasation.[1] Penetrating injuries account for 10% of all injuries sustained by the pediatric population, with the majority caused by firearms. Pediatric surgeons play a critical role in the care of children in pediatric trauma centers, as FI is the second leading cause of mortality among this group.[2] FIs in children are less common than in adults. However, they typically result in more severe injuries, often necessitating extensive surgical interventions and leading to higher morbidity and mortality rates.[3] The thinner body walls and smaller anatomical size of children increase their susceptibility to severe trauma, which can range from minor injuries to life-threatening conditions depending on the bullet's trajec-

Cite this article as: Erten EE, Öztorun Cİ, Ertürk A, Bostancı SA, Demir S, Şahin VS, et al. Firearm injuries in pediatric surgery: Pediatric trauma center experiences. Ulus Travma Acil Cerrahi Derg 2025;31:540-547.

Address for correspondence: Elif Emel Erten
Department of Pediatric Surgery, Ankara Bilkent City Hospital, Ankara, Türkiye
E-mail: elifemelerten@hotmail.com

Ulus Travma Acil Cerrahi Derg 2025;31(6):540-547 DOI: 10.14744/tjtes.2024.25224
Submitted: 07.12.2023 Revised: 01.11.2024 Accepted: 30.11.2024 Published: 05.06.2025
OPEN ACCESS This is an open access article under the CC BY-NC license (http://creativecommons.org/licenses/by-nc/4.0/).

tory through anatomical structures and its potential to cause multiple organ dysfunction or death.[4] It is essential to maintain objectivity when discussing the severity of these injuries and to use precise language in their description.

The aim of this study was to assess the data, treatment methods, and outcomes for children with FIs referred to a pediatric trauma center.

MATERIALS AND METHODS

This retrospective study included pediatric patients admitted to the pediatric trauma center of our hospital for thoracic and abdominal firearm injuries, who were treated in the pediatric surgical intensive care unit between 2015 and 2021. Data were collected and analyzed regarding demographic characteristics, time of injury, Glasgow Coma Scale (GCS) scores, Penetrating Trauma Score (PTS), mechanism of injury (accidental or intentional), affected organs, treatments administered, removal of foreign bodies, and length of hospitalization.

Surgical intervention was performed for patients who were hemodynamically unstable, had organ perforations, and/or presented with a major anterior abdominal wall defect or evisceration. In cases of respiratory difficulty due to pneumothorax or hemothorax, tube thoracostomy was frequently performed. Thoracotomy was also employed for foreign body removal and bleeding control.

Patients were categorized into three groups based on the location of their injury: thoracic, abdominal, or thoracoabdominal. Comparisons were made within and between these groups to identify any significant differences. Patients who underwent laparotomy or thoracotomy, or those who had a foreign body removed from deep tissues, were classified as having undergone major surgery, whereas those treated with tube thoracostomy were considered to have undergone minor surgery. Patients who did not require surgery but retained foreign bodies in the chest or abdomen were classified under conservative management.

This study was approved by the Ankara City Hospital Ethics Committee (Date: 27.04.2021, Decision No: 77.637.435/189) and in accordance with the principles of the Declaration of Helsinki.

Statistical Analysis

Statistical analysis was performed using IBM SPSS Statistics software, version 26.0 (IBM Corp., Armonk, NY, USA). Categorical variables were analyzed using frequencies and percentages, and numerical variables were analyzed using descriptive statistics (mean and standard deviation). The Shapiro-Wilk test was used to assess the normality of the numerical data, which were found to be non-normally distributed. Consequently, non-parametric tests were employed: the Spearman's rho correlation coefficient was used to assess correlations between two numerically independent variables; the Mann-Whitney U test was used to compare two independent groups; and the Kruskal-Wallis test was used for comparisons among more than two groups. Chi-square analysis and Fisher's exact test were applied to examine relationships between two independent categorical variables. Statistical significance was set at $p<0.05$ for all tests.

RESULTS

A total of 32 patients suffering from thoracic and/or abdominal FIs were included in this study. The mean age of the patients was 12.43±2.31 years, with 27 males (84.4%) and five females (15.6%). Twelve patients (37.5%) were admitted during the daytime, 15 (46.9%) in the evening, and five (15.6%) at night. The patients had a mean GCS score of 14.69±6.34 (range: 3-15) and a mean PTS of 8.47±2.69 (range: 2-11). Sixteen patients (50%) were injured accidentally, while 16 patients were injured intentionally, including three o who sustained injuries due to suicide attempts. The median age of the three patients who attempted suicide was 14 years (range: 13-15). Twenty-one patients (65.6%) were injured by bullets, while 11 patients (34.4%) were injured by pellet guns. The mean age of patients with intentional injuries was 14.63±2.55 years, whereas the mean age of patients with unintentional injuries was 11.19±3.69 years. A statistically significant association was found between accidental injury and age, with younger patients more likely to be victims of accidental firearm injuries ($p=0.002$).

Table 1 shows that there was no statistically significant association between the nature of firearm injury (intentional or accidental) and gender, time of injury, GCS, PTS, type of foreign body (bullet or pellet), foreign body status (removed or not), presence of thoracic pathology, presence of abdominal pathology, type of intervention performed, or length of hospital stay ($p>0.05$).

The study participants were divided into three groups according to the affected organs. Group 1 consisted of nine patients with injuries to the thorax only; Group 2 included fifteen patients with injuries to the abdomen only; and Group 3 comprised eight patients with injuries to both the thorax and the abdomen.

Three patients with thoracic injuries (Group 1) underwent major surgery. Two patients underwent thoracotomy due to hemodynamic instability, and a bullet was extracted from the lung parenchyma. In one case, a thoracotomy was performed to repair injuries to the lung and esophagus. Three patients with hemothorax were treated with tube thoracostomy alone, as they were hemodynamically stable despite the presence of bullet and pellet fragments in the chest wall. Two patients had bullet entry and exit wounds in the thorax (Fig. 1). Imaging revealed no serious injuries, and both patients remained stable. In these two cases, only tube thoracostomy

Table 1. Distribution of patient characteristics by type of injury formation

	Intentional (n=16)	Accidental (n=16)	p
Gender n,%			
Male	13 (81.3)	14 (87.5)	1.000
Female	3 (18.8)	2 (12.5)	
Time of Injury n,%			
08:00-17:00	5 (31.3)	7 (43.8)	0.802
17:00-24:00	8 (50.0)	7 (43.8)	
24:00-08:00	3 (18.8)	2 (12.5)	
Foreign Body Type n,%			
Pellet	7 (43.8)	4 (25.0)	0.264
Bullet	9 (56.3)	12 (75.0)	
Foreign Body Condition n,%			
Retained	6 (37.5)	6 (37.5)	1.000
Removed	10 (62.5)	10 (62.5)	
Thoracic Pathology n,%			
Yes	7 (43.8)	10 (62.5)	0.288
No	9 (56.3)	6 (37.5)	
Abdominal Pathology n,%			
Yes	13 (81.3)	10 (62.5)	0.433
No	3 (18.8)	6 (37.5)	
Treatment Method n, %			
Minor Surgery	3 (18.8)	5 (31.3)	0.754
Major Surgery	11 (68.8)	10 (62.5)	
Conservative Treatment	2 (12.5)	1 (6.3)	
Age (years)	14.63±2.55	11.19±3.69	0.002*
GCS	14.19±2.32	13.81±3.25	0.985
PTS	8.63±1.41	8.19±2.81	0.956
Length of Hospitalization (days)	14.13±12.26	12.44±8.56	0.985



Figure 1. Entry and exit wounds in thoracic firearm injury. Bilateral thoracic entry and exit bullet wounds are visible.

was required. Although one patient had bullet fragments in the thorax, no pneumothorax or hemothorax was observed on imaging, and no intervention was required as the patient remained hemodynamically stable (Fig. 2).

Ten of the 15 patients in Group 2 with abdominal injuries underwent laparotomy due to hemodynamic instability and perforation of intra-abdominal organs. In one patient with multiple organ injuries, cholecystectomy was performed along with bleeding control and primary repair following the removal of pellets from the liver and spleen. Another patient with bowel and colon injuries underwent ileal resection and colostomy. In four cases, a retroperitoneal small hematoma was caused by bullet and pellet fragments, which were removed when located between the subcutaneous and muscle planes. In the remaining cases, primary surgical repair was performed due to perforation of a hollow organ.

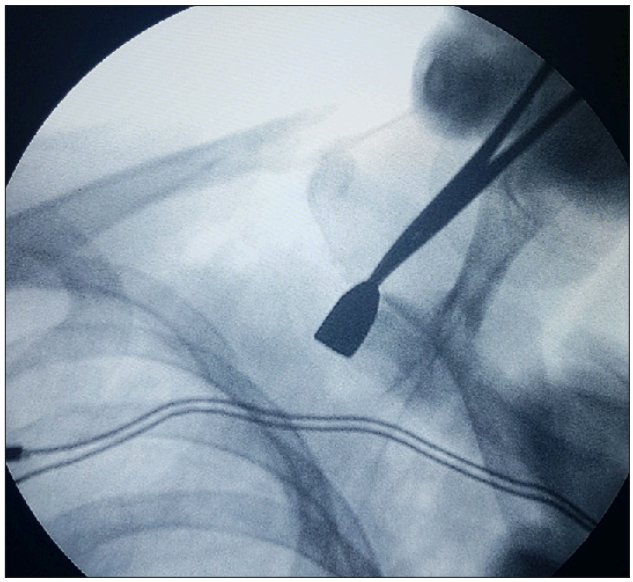

Figure 2. Thoracic imaging shows bullet fragments lodged in the chest wall, without evidence of pneumothorax or hemothorax.

Four of the eight patients in Group 3, who had sustained both thoracic and abdominal injuries, required major surgery. Two patients underwent both thoracotomy and laparotomy: one had a bullet removed from the thorax along with repair of an abdominal peritoneal hematoma (Fig. 3), and the other had multiple pellets removed from the lung parenchyma and abdomen, as well as repairs for perforations of the spleen, liver, diaphragm, stomach, small intestine, and colon. Two other patients had multiple organ perforations in the lung and abdomen caused by bullets. They underwent tube thoracostomy and abdominal bullet removal, followed by repair of the multiple organ perforations. In three patients, bullet and pellet fragments caused hemothorax and hemorrhage near the liver and kidney; however, their hemodynamic stability was not compromised. Minor surgery in the form of tube thoracostomy was performed in these patients. The most frequently affected organs were the colon (n=9), small intestine (n=6), and stomach (n=4) ($p<0.05$). The affected abdominal organs are listed in Table 2.

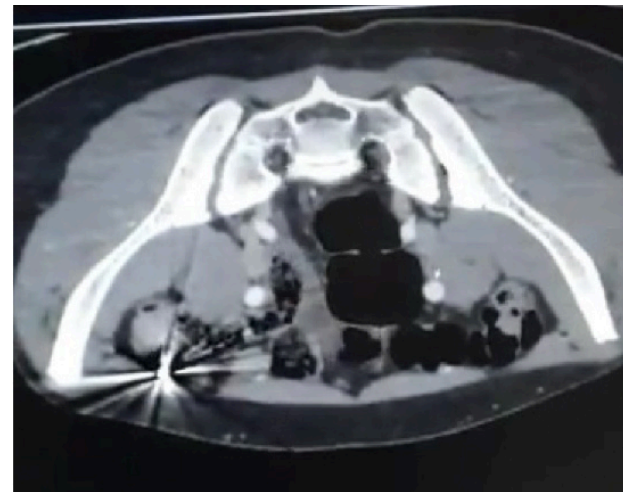

Figure 3. A penetrating bullet injury sustained damage to both thoracic and abdominal structures.

The mean length of hospital stay was 13.08±9.34 days. Table 3 presents the group information and the results of the statistical comparison. There were no statistically significant differences between groups with respect to gender, age, time of injury, GCS, PTS, type of foreign body, foreign body status, or length of hospital stay ($p>0.05$).

Additionally, treatment methods for thoracic and abdominal injuries were compared. Among patients with thoracic injuries, 41% (7 out of 17) underwent major surgeries, 47% (8 out of 17) underwent minor surgeries, and 12% (2 out of 17) were managed conservatively without surgery. In contrast, among patients with abdominal injuries, 78.2% (18 out of 23) required major surgeries, while the remaining 22% (5 out of

Table 2. Affected organs in the presence of abdominal pathology

Organ	No Laparotomy (n=18)		Laparotomy (n=14)		p
	n	%	n	%	
Spleen	1	5.6	2	14.3	0.568
Liver	1	5.6	1	7.1	1.000
Small Intestine	0	0.0	6	42.9	0.003*
Stomach	0	0.0	4	28.6	0.028*
Gallbladder	0	0.0	1	7.1	0.437
Pancreas	0	0.0	1	7.1	0.437
Colon	0	0.0	9	64.3	0.000*
Retroperitoneum	3	16.7	2	14.3	1.000
Diaphragm	0	0.0	4	21.4	0.073
Kidney	1	5.6	0	0.0	1.000

Table 3. Distribution of characteristics by location of pathology

	Thorax (n=9)	Abdomen (n=15)	Thorax and Abdomen (n=8)	p
Gender n,%				
Male	8 (88.9)	11 (77.3)	8 (100)	0.336
Female	1 (11.1)	4 (26.7)	0	
Time of Injury n,%				
08:00-17:00	3 (33.3)	5 (33.3)	4 (50.0)	
17:00-24:00	3 (33.3)	8 (53.3)	4 (50.0)	0.525
24:00-08:00	3 (33.3)	2 (13.4)	0	
Foreign Body Type n,%				
Pellet	1 (11.1)	6 (40.0)	4 (50.0)	0.202
Bullet	8 (88.9)	9 (60.0)	4 (50.0)	
Foreign Body Condition n,%				
Retained	4 (44.4)	3 (20.0)	5 (62.5)	0.118
Removed	5 (55.6)	12 (280.0)	3 (37.5)	
Treatment Method				
Minor Surgery	5 (56.6)	0	3 (37.5)	0.003*
Major Surgery	3 (33.3)	14 (93.3)	4 (50.0)	
Conservative Treatment	1 (11.1)	1 (6.7)	1 (12.5)	
Age (years)	11.56±4.13	13.33±3.92	13.63±1.77	0.382
GCS	15.00	14.27±1.67	12.38±4.93	0.247
PTS	9.11±1.17	8.67±2.16	7.13±2.80	0.401
Length of Hospitalization (days)	13.22±12.88	12.33±8.63	15.13±11.73	0.926

23) were treated conservatively. Statistical analysis revealed a significant difference between the treatment approaches for thoracic and abdominal injuries, with a p-value of 0.02. This indicates that the location of the injury significantly influences the choice of treatment.

Surgical treatments were evaluated according to the location of the injury and the type of foreign body. In cases involving both thoracic and abdominal injuries, individuals wounded by bullets were more likely to undergo major surgical interventions, whereas those injured by pellets were typically managed with minor surgical procedures (p=0.08) (Table 4).

Data on children who died due to firearm injuries during the same period as this study were collected and analyzed from the regional forensic medicine institution. A total of 30 victims were identified, including 24 males and six females. The average age was 14.83 years, ranging from 1 to 18 years. Nine victims had both thoracic and abdominal injuries, 16 had thoracic injuries only, and five had abdominal injuries only. Among them, 11 patients were injured by bullets, while 19 patients sustained fatal injuries from shotgun pellets. The findings indicated that thoracic injuries were more common than abdominal injuries and were more likely to result in death. Another significant finding was that the majority of fatalities occurred due to shotgun pellet injuries.

The mean length of hospital stays for patients who underwent major surgery was 17.05±11.06 days, compared to 6.63±2.67 days for those who underwent minor surgery and 4.67±1.57 days for those who received conservative therapy. There was a statistically significant difference between the groups (p<0.001).

Eleven patients were followed up after bullet or pellet frag-

Table 4. Surgical treatment according to the location of injury and type of foreign body

Thorax			**p**
	Major Surgery	Minor Surgery	
Bullet	5	2	
Pellet	2	6	0.08
Abdomen			
	Major Surgery	Minor Surgery	
Bullet	11	2	
Pellet	8	2	

ments were intentionally left in deep tissues of the body, as their removal would have posed a risk of greater tissue damage and they had not caused hemodynamic instability or organ perforation. The mean duration of follow-up was 19 months (range: 8-36 months). No complications were observed during the follow-up period.

DISCUSSION

Firearm injuries (FIs) represent a significant cause of mortality in pediatric trauma settings, with the majority of cases managed by pediatric surgeons. Prior studies have indicated that most pediatric FIs affect males aged 14 years or younger, with accidental injuries more common in younger children and intentional injuries occurring more frequently in older children.[5,6] Our study found that, consistent with existing literature, patients with intentional firearm injuries were older on average than those with accidental injuries, with a mean age of 14.63 years compared to 11.19 years, respectively. This study's age distribution supports these findings, demonstrating that accidental firearm injuries occur at a younger average age than intentional injuries.

Interestingly, our data did not support previous research[7] suggesting that firearm injuries are more frequent during evening hours. Instead, our analysis showed no significant time-related trends. This may reflect variations in community behaviors or the effectiveness of curfew and supervision policies during evening hours.

The most common abdominal organs affected by FIs are the small bowel and large bowel, reported in 40% to 50% of cases.[8] Our research similarly found that the colon and small intestine (42.9%-64.3%) were the most frequently affected organs, consistent with the literature. Medical literature also supports that early primary anastomosis of bowel injuries in children with penetrating trauma is safer than colostomy, as colostomy is associated with longer hospital stays and higher complication rates when it can be avoided.[9] In our series, we excised and anastomosed a portion of the bowel in appropriate cases. One patient with multiple colonic perforations and pellet injuries underwent a colostomy, which was closed two months later.

Thoracic FIs result in severe lung tissue destruction due to the high temperature and pressure generated by the bullet's entry into the body, often leading to hemothorax or pneumothorax.[10] Conservative treatment is usually sufficient for lung lacerations, and surgical intervention is generally not required. For most patients, tube thoracostomy is adequate.[10] Surgery may be considered in cases of severe pulmonary parenchymal laceration or damage to the vascular, cardiac, tracheal, or esophageal systems.[11] In our study, conservative management proved sufficient for many thoracic injuries, particularly those without significant vascular or organ damage. This aligns with the literature, which suggests that non-operative management can be effective for certain thoracic firearm injuries, especially when no immediate life-threatening complications are present.[11]

For abdominal injuries, however, surgical intervention is often necessary due to the risk of damage to multiple internal organs, in accordance with international guidelines.[12] Bullet injuries, due to their higher kinetic energy, tend to cause more severe trauma and frequently require major surgical interventions, whereas pellet injuries often result in minor injuries that can be managed conservatively.[13]

In a study of 267 children with penetrating thoracic trauma, 74.5% were treated with tube thoracostomy alone, while 18.6% were managed conservatively.[14] In our study, 47% of the 17 patients with thoracic injuries were treated with tube thoracostomy, while 23% were treated conservatively.

The long-term management of retained foreign bodies remains a controversial issue. A study by Mazotas et al. revealed that 44% of patients retained foreign bodies, with 22% experiencing complications such as infections, which was the most common issue. This study also highlighted the long-term effects of retained foreign bodies from firearm wounds in children.[14] In our research, 12 patients (37.5%) retained foreign bodies that could not be removed, including five bullets and seven pellets. During the follow-up period, these patients did not exhibit any complications. Interestingly, our study observed a lower complication rate associated with retained foreign bodies, contrasting with other reports that suggest a higher risk of infection and additional complications. This discrepancy could be attributed to variations in the severity of the injuries, the type of foreign bodies involved, or differences in local wound care protocols.

Firearm injuries often leave unclear traces that make anatomical identification difficult.[15] Pediatric penetrating injuries caused by firearms can have severe effects on multiple organ systems. A single bullet can injure both thoracic and abdominal organs along its trajectory. In our dataset, eight victims sustained injuries to organs in both the thorax and abdomen despite having a single bullet entry point. Patients should undergo regular monitoring and evaluation for abdominal injury, even if there is no evidence of hemodynamic instability or peritonitis at the time of injury. In cases of thoracic trauma, a foreign body traveling into the thorax may cause perforation of the diaphragm and stomach, leading to serious complications.

Most FI mortalities occur within the first 24 hours following trauma and at the location where the injury occurred.[16] None of the victims in our study died; however, during the same period, among children who succumbed to firearm injuries, it was observed that males had a higher incidence of thoracic injuries and injuries caused by pellets. These findings suggest that thoracic injuries resulting from firearm incidents may have a higher mortality rate than injuries to major organs such as the large arteries, trachea, and heart.

While we believe that the prompt and effective hemodynamic management of patients in our emergency department may have contributed to these favorable outcomes, we also acknowledge that individuals with more severe vascular and critical organ injuries may have died at the scene and were therefore unable to be transported to the hospital.

CONCLUSION

The management of FIs in children is a complex process that requires the implementation of timely and multifaceted interventions. This study demonstrates that thoracic injuries often respond well to conservative treatments, except in cases where patients die at the scene or in the emergency department due to injuries to major organs or large arteries. In contrast, abdominal injuries frequently require extensive surgical intervention due to the serious complications they can cause. The findings of this research highlight the necessity for age-specific preventive measures, as younger children are more frequently the victims of accidental injuries, while older children are at a higher risk of sustaining intentional injuries.

Effective management of pediatric trauma necessitates prompt medical intervention, complemented by community and policy initiatives focused on prevention and education. These initiatives are crucial for decreasing the incidence of injury and enhancing outcomes in pediatric trauma settings.

Ethics Committee Approval: This study was approved by the Ankara City Hospital Ethics Committee (Date: 27.04.2021, Decision No: 77.637.435/189)

Peer-review: Externally peer-reviewed.

Authorship Contributions: Concept: E.E., M.N.A., E.Ş.; Design: E.E., C.İ.O., S.D.; Supervision: C.İ.O., A.E., B.D., S.D.; Data collection and/or processing: A.E., B.D., S.Ö., S.A.B., S.A.B., V.S.Ç., E.E.; Analysis and/or interpretation: A.E., S.A.B., V.S.Ç., E.E., B.D., S.Ö.; Literature review: E.E., C.İ.O., S.D.; Writing: E.E., C.İ.O., M.N.A., E.Ş.; Critical review: E.E., M.N.A., E.Ş.

Conflict of Interest: None declared.

Financial Disclosure: The author declared that this study has received no financial support.

REFERENCES

1. Bayouth L, Lukens-Bull K, Gurien L, Tepas JJ 3rd, Crandall M. Twenty years of pediatric gunshot wounds in our community: Have we made a difference? J Pediatr Surg 2019;54:160–4. [CrossRef]
2. Lynch T, Kilgar J, Al Shibli A. Pediatric abdominal trauma. Curr Pediatr Rev 2018;14:59–63. [CrossRef]
3. Stevens J, Leonard J, Reppucci ML, Schroeppel T, Bensard D, Haasz M. Individual and neighborhood level characteristics of pediatric firearm injuries presenting at trauma centers in Colorado. J Trauma Acute Care Surg 2022;93:385–93. [CrossRef]
4. Sandler G, Leishman S, Branson H, Buchan C, Holland AJ. Body wall thickness in adults and children—Relevance to penetrating trauma. Injury 2010;41:506–9. [CrossRef]
5. Nordin A, Coleman A, Shi J, Wheeler K, Xiang H, Kenney B. In harm's way: Unintentional firearm injuries in young children. J Pediatr Surg 2018;53:1020–3. [CrossRef]
6. Hughes BD, Cummins CB, Shan Y, Mehta HB, Radhakrishnan RS, Bowen-Jallow KA. Pediatric firearm injuries: Racial disparities and predictors of healthcare outcomes. J Pediatr Surg 2020;55:1596–603. [CrossRef]
7. Davis JS, Castilla DM, Schulman CI, Perez EA, Neville HL, Sola JE. Twenty years of pediatric gunshot wounds: An urban trauma center's experience. J Surg Res 2013;184:556–60. [CrossRef]
8. Ranney ML. Pediatric firearm injuries and fatalities. Ann Emerg Med 2021;78:695. [CrossRef]
9. Haut ER, Nance ML, Keller MS, Groner JI, Ford HR, Kuhn A, et al. Management of penetrating colon and rectal injuries in the pediatric patient. Dis Colon Rectum 2004;47:1526–32. [CrossRef]
10. Alaqeel SM, Howsawi AA, Al Namshan MK, Al Maary JO. Patterns of pediatric thoracic penetrating injuries: A single-trauma-center experience in Riyadh, Saudi Arabia. Saudi Med J 2021;42:280–3. [CrossRef]
11. Elkbuli A, Meneses E, Kinslow K, McKenney M, Boneva D. Successful management of gunshot wound to the chest resulting in multiple intra-abdominal and thoracic injuries in a pediatric trauma patient: A case report and literature review. Int J Surg Case Rep 2020;76:372–6. [CrossRef]
12. Durso AM, Paes FM, Caban K, Danton G, Braga TA, Sanchez A, et al. Evaluation of penetrating abdominal and pelvic trauma. Eur J Radiol 2020;130:109187. [CrossRef]
13. Baum GR, Baum JT, Hayward D, MacKay BJ. Gunshot wounds: Ballistics, pathology, and treatment recommendations, with a focus on retained bullets. Orthop Res Rev 2022;14:293–317. [CrossRef]
14. Mazotas IG, Hamilton NA, McCubbins MA, Keller MS. The long-term outcome of retained foreign bodies in pediatric gunshot wounds. J Trauma Nurs 2012;19:240–5. [CrossRef]
15. Sakamoto R, Matsushima K, de Roulet A, Beetham K, Strumwasser A, Clark D, et al. Nonoperative management of penetrating abdominal solid organ injuries in children. J Surg Res 2018;228:188–93. [CrossRef]
16. Feldman KA, Tashiro J, Allen CJ, Perez EA, Neville HL, Schulman CI, et al. Predictors of mortality in pediatric urban firearm injuries. Pediatr Surg Int 2017;33:53–8. [CrossRef]

ORİJİNAL ÇALIŞMA - *ÖZ*

Çocuk cerrahisinde ateşli silah yaralanmaları: Pediatrik travma merkezi deneyimleri

AMAÇ: Bu çalışmada, bir pediatrik travma merkezinde pediatrik cerrahları tarafından tedavi edilen torakal ve abdominal ateşli silah yaralanması olan çocuk hastalara ilişkin epidemiyolojik verileri değerlendirmeyi amaçladık.
GEREÇ VE YÖNTEM: 2015-2022 yılları arasında ateşli silah yaralanması nedeni ile hastaneye yatırılan çocuklar retrospektif olarak incelendi. Hastaların demografik özellikleri, etkilenen organlar, tedavi yöntemleri ve hastanede kalış süresi analiz edildi.
BULGULAR: Hastaların ortalama yaşı 12.43±2.31 yıldı; 27'si (%84.4) erkek, beşi (%15.6) kadındı. Mermi yaralanmaları daha yüksek şiddetle ilişkilendirildi ve sıklıkla majör cerrahi müdahale gerektirirken, saçma yaralanmaları genellikle konservatif olarak tedavi edildi. Torasik yaralanmalarda, konservatif yönetimin hayatı tehdit eden acil komplikasyonları olmayan stabil vakalar için etkili olduğu düşünülürken, abdominal yaralanmalar daha sıklıkla invaziv cerrahi yaklaşımlar gerektirmiştir. Özellikle, kaza ile olan ateşli silah yaralanmaları küçük çocuklarda daha yaygınken, kasıtlı yaralanmalar daha büyük ergenlerde daha yaygındı. Yaş ve ateşli silah yaralanması türü arasında istatistiksel olarak anlamlı bir korelasyon olduğunu gösterildi (p=0.002). Ayrıca, göğüs yaralanması olan hastaların çoğuna minör cerrahi uygulanırken, karın yaralanması olan hastalara çoğunlukla majör cerrahiler uygulanmıştır
SONUÇ: Araştırmamızda, kaza ile olan ateşli silah yaralanmalarının genç yaş gruplarında daha yaygın olduğunu, kasıtlı ateşli silah yaralanmalarının yaşla birlikte arttığını gösterdik.

Anahtar sözcükler: Ateşli silah yaralanması; çocuklarda travma; göğüs travması; karın travması.

Ulus Travma Acil Cerrahi Derg 2025;31(6):540-547 DOI: 10.14744/tjtes.2024.25224