Ann Thorac Cardiovasc Surg 2021; 27: 164–168
Online November 6, 2020
doi: 10.5761/atcs.oa.20-00178

Original Article

Evaluating Giant Hydatid Cysts: Factors Affecting Mortality and Morbidity

Mustafa Vedat Dogru, MD, Celal Bugra Sezen, MD, Cemal Aker, MD, Volkan Erdogu, MD, Semih Erduhan, MD, Levent Cansever, MD, and Muzaffer Metin, MD

Objective: The aim of this study was to evaluate the prognostic factors affecting morbidity and mortality among patients who underwent surgery for giant pulmonary hydatid cysts in our center.
Methods: Data from 283 patients who underwent surgery in our center for pulmonary hydatid cyst between 2008 and 2018 were retrospectively analyzed. Cysts 10 cm in diameter or larger were considered giant hydatid cysts.
Results: There were 145 women (51.2%) and 138 men (48.8%). Giant cyst (≥10 cm) was present in 57 patients (20.1%), while the other 226 patients (79.9%) had cysts smaller than 10 cm. Operations were performed using videothoracoscopic approach in 68 patients (24%) and with thoracotomy in 215 patients (76%). Hydatid cysts were on the left side in 129 patients (45.6%), on the right side in 143 patients (50.5%), and bilateral in 11 patients (3.9%). Postoperative morbidity occurred in 29 patients (10.2%). Use of videothoracoscopic surgical approach did not affect morbidity. The mortality rate within the first 90 days was 0.35% (n = 1).
Conclusion: Giant cysts are more common in the young age group than in older adults. Regardless of cyst size, surgery should be performed as soon as possible after diagnosis to avoid potential complications.

Keywords: morbidity, hydatid cyst, surgery, prognostic factors

Introduction

Hydatid cyst is caused by *Echinococcus granulosus* and is the most common parasitic infection of the lung. Hydatid disease most frequently affects the liver (50–60%, followed by the lung (18–35%). It is an endemic parasitosis common in developing countries.[1)] Hydatid cysts are typically considered giant when they reach 10 cm in diameter or larger. Giant cysts are particularly difficult to treat.[2–4)] There are a limited number of studies on giant cysts in the literature.[1,4–6)]

The aim of this study was to evaluate the prognostic factors affecting morbidity and mortality and the incidence of recurrence among patients who underwent surgery for giant pulmonary hydatid cysts in our center.

Materials and Methods

Patients who underwent operations in our center due to pulmonary hydatid cyst between 2008 and 2018 were evaluated retrospectively. Patients with missing data or irregular follow-up were excluded from the study. A total

Department of Thoracic Surgery, University of Health Sciences Turkey, Yedikule Chest Diseases and Thoracic Surgery Training and Research Hospital, Istanbul, Turkey

Received: June 15, 2020; Accepted: July 14, 2020
Corresponding author's: Mustafa Vedat Dogru, MD. Yedikule Chest Diseases and Thoracic Surgery Training and Research Hospital, Kazlicesme Mh, Belgrade Kapi yolu Cad No: 1, Zeytinburnu, Istanbul 34020, Turkey
Email: drmvedatdogru@hotmail.com

This work is licensed under a Creative Commons Attribution-NonCommercial-NoDerivatives International License.
©2021 The Editorial Committee of *Annals of Thoracic and Cardiovascular Surgery*

of 283 patients were evaluated in two groups: those cysts 10 cm (Group A) or smaller in diameter according to preoperative tomographic examination and those with cysts 10 cm or larger (Group B) in diameter (giant cyst).

All patients were evaluated preoperatively using thoracic and abdominal computed tomography (CT). Pulmonary reserve was assessed by pulmonary function tests. Patients with a history of cardiac disease and patients aged 60 years or older were evaluated using echocardiogram in the cardiology department. Indirect hemagglutination assay was performed at initial diagnosis in 201 cases.

The study was approved by the institutional review board and conducted in accordance with the principles of the Declaration of Helsinki.

Surgical procedure

Patients were intubated with a double-lumen endotracheal tube before the operation. If the cyst was located deep in the parenchyma, the cyst fluid was drained using needle aspiration. After the germinative membrane was removed, the chest cavity was irrigated using 0.04% chlorhexidine gluconate or hypertonic solutions and segmental bronchial leaks were closed using 3-0 polypropylene (Prolene) sutures. The cyst cavity was obliterated using 3-0 vicryl sutures (**Fig. 1**).

In the videothoracoscopic approach, cystotomy and capitonnage were performed for cysts 2 cm or larger in size, while wedge resection was performed for cysts 2 cm or smaller in size according to surgeon preference.

Postoperative follow-up

Patients were reanimated in the operating room and monitored in the surgical intensive care unit until their general condition stabilized. Intravenous analgesic therapy was used for pain management. Chest tubes were removed when daily drainage volume was less than 100 mL.

The patients were analyzed in terms of demographic data, length of hospital stay, morbidity, mortality, and recurrence. Patient follow-up information was obtained through office visits or telephone interviews with the patient, a relative, or their primary physicians.

The patients received albendazole 10 mcg/kg/day postoperatively for approximately 6–9 months.

Statistics

Descriptive statistics were used to evaluate relationships between the patients' demographic and clinical data; relationships between categorical data were evaluated using chi-square (χ^2) or Fisher's exact test. Student's t-test, Mann–Whitney U test, and Kruskal–Wallis test were used for continuous variables. A p value less than 0.05 was considered significant. SPSS statistics software package (version 22, SPSS, Inc., Chicago, IL, USA) was used for analyses.

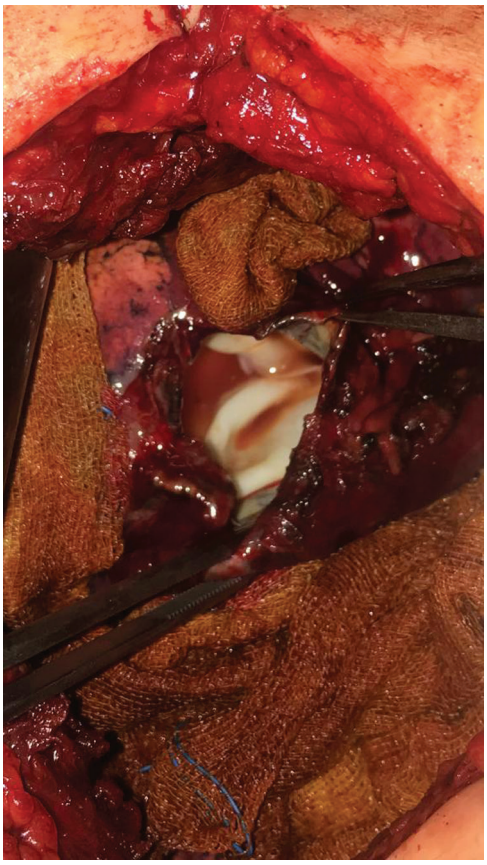

Fig. 1 Intraoperative view of cystotomy of the hydatid cyst

Results

A total of 382 patients (145 females [51.2%] and 138 males [48.8%]) were included in the study. The mean age was 35.9 ± 15.8 (12–76) years; 261 patients (92.2%) were below 65 years of age and 22 (7.8%) were over 65 years of age. Operations were performed using the videothoracoscopic approach in 68 patients (24%) and by thoracotomy in 215 patients (76%). Hydatid cysts were on the left side in 129 patients (45.6%), on the right side in 143 patients (50.5%), and bilateral in 11 patients (3.9%). The mean FEV_1 was 2.51 ± 0.77 L (81.90 ± 19.93% of predicted). Mean cyst diameter measured on tomography was 6.49 ± 3.75 cm. Cystotomy and capitonnage were performed in 213 (75.3%) patients, while

Table 1 Comparison of demographic characteristics by groups

Variables		Group A		Group B		*p* Value
		n	%	*n*	%	
Age (Year) Mean ± StD		37 ± 15.53		32.01 ± 16.37		0.009
Age	<65	210	92.9	51	89.5	0.385
	>65	16	7.1	6	10.5	
Sex	Male	110	48.7	28	49.1	0.952
	Female	116	51.3	29	50.9	
CCI	0	188	83.2	51	89.5	0.242
	1	38	16.8	6	10.5	
Symptoms	Asymptomatic	73	32.3	5	8.8	<0.001
	Symptomatic	153	67.7	52	91.2	
Side	Right	112	49.6	31	54.4	0.579
	Left	104	46	25	43.9	
	Bilateral	10	4.4	1	1.8	
Operation	Cystotomy: Capitonnage	160	70.8	53	93	0.004
	Wedge	34	15	0	0	
	Lobectomy	30	13.3	4	7	
	Segmentectomy	2	0.9	0	0	
Operation	VATS	62	27.4	6	10.5	0.008
	Thoracotomy	164	72.6	51	89.5	

Group A cysts smaller than 10 cm and Group B cysts larger than 10 cm. CCI: Charlson Comorbidity Index; StD: standard deviation

34 (12.2%) patients underwent wedge resection, 34 (12.2%) patients underwent lobectomy, and 2 (0.7%) patients underwent segmentectomy. Giant cyst (≥10 cm) was present in 57 patients (20.1%), while the other 226 patients (79.9%) had cysts smaller than 10 cm. The mean length of hospital stay was 5 days. In all, 78 patients (27.6%) were asymptomatic and 205 patients (72.4%) were symptomatic at the time of admission (**Table 1**).

In all, 32 postoperative morbidities occurred in 29 patients (10.2%). Persistent air leak (PAL) was observed in 12 patients (4.2%). Six patients with PAL underwent revision, while another two patients underwent blood pleurodesis. Air leak resolved spontaneously in four patients. Four patients developed respiratory failure postoperatively. Respiratory failure developed in three patients undergoing cystotomy and capitonnage and one patient undergoing lobectomy. Three of these patients improved with noninvasive mechanical ventilation, while lobectomy patient died due to postoperative acute respiratory distress syndrome (ARDS). In the patient who developed ARDS, prolonged air leak was not spontaneously regressed, and blood pleurodesis was performed. The patient had increased white blood cell counts and C-reactive protein levels with bilateral infiltration at chest X-ray. The patient was followed up as intubated. Piperacillin/Tazobactam and ciprofloxacin treatment were used for severe pneumonia. Two patients (0.7%) developed subcutaneous emphysema. Another two patients (0.7%) developed postoperative bronchial leak. While one patient underwent completion lobectomy and one patient underwent primary fistula repair. Three patients developed empyema after discharge and were managed with tube thoracostomy and antibiotic therapy. Wound site infection occurred in eight patients (2.8%). One patient (0.4%) underwent revision due to hemorrhage. Factors affecting morbidity are shown in **Table 2**. During the first 90 days, one patient died due to ARDS.

Postoperative recurrence occurred in eight patients (2.8%), all of whom had undergone thoracotomy. Recurrence was attributed to continued exposure to animals.

Discussion

Hydatid disease is more common in populations with low socioeconomic status. It occurs more frequently in the rural areas of endemic countries. Similarly, 87% of pulmonary hydatid cyst cases in Turkey occur in rural areas.[7] Although detected more frequently in men, the disease does not affect the sexes differently.[7] Giant cysts are usually observed as a result of late diagnosis and treatment. While there is no clear definition of "giant" cysts in the literature, Karaoglanoglu et al. defined giant cysts as those that are 10 cm or larger.[6] We used this definition in the present study.

Table 2 Risk factors affecting morbidity

Variables		Morbidity No		Morbidity Yes		*p* Value
		n	%	*n*	%	
Age	<65	236	92.9	25	86.2	0.201
	>65	18	7.1	4	13.8	
Sex	Male	122	48	16	55.2	0.466
	Female	132	52	13	44.8	
Side	Right	120	47.2	9	31	0.228
	Left	124	48.8	19	65.5	
	Bilateral	10	3.9	1	3.4	
CCI	0	214	84.3	25	86.2	0.783
	>1	40	15.7	4	13.8	
Operation	VATS	58	22.8	10	34.5	0.164
	Thoracotomy	196	77.2	19	65.5	
Cyst	<10 cm	207	81.5	19	65.5	0.042
	>10 cm	47	18.5	10	34.5	
Operation	Cystotomy: Capitonnage	194	76.4	19	65.5	0.433
	Wedge	28	11	6	20.7	
	Lobectomy	30	11.8	4	13.8	
	Segmentectomy	2	0.8	0	0	

CCI: Charlson Comorbidity Index; StD: standard deviation

Although hydatid cysts are observed in all age groups, they occur more frequently in young adults. Cysts grow more rapidly in young patients than in older patients. Therefore, giant cysts are seen more frequently in children aged 10 or younger. The higher frequency of giant cysts among children and adolescents in particular has been attributed to their immune systems still being not fully developed.[3,8–10] We also found that giant cysts were more common in the young age group in our study.

Pulmonary hydatid cysts are more frequently found on the right side and in the lower lobes.[11–13] While 10%–19% of hydatid cysts are asymptomatic, symptoms caused by mass effect may occur depending on lesion size. Patients may have chest pain, difficulty breathing, hemoptysis, allergic reactions, and hydatoptysis.[3,11,13,14] In our study, 205 patients (72.4%) were symptomatic overall, while 52 (91.2%) of patients with giant cyst were symptomatic. The most common symptom is cough.

Anaphylactic reaction occurs as a result of ruptured cysts draining into the pleural cavity or bronchus. The cyst membrane may also cause bronchial obstruction, and atelectasis may occur.[1] Therefore, we believe immediate surgery is imperative in the event of a ruptured cyst.

Today, lung-sparing procedures are preferred whenever possible. However, lobectomy or less commonly pneumonectomy is performed in patients with lesions affecting 50% or more of the lung and those with chronic abscess, bronchiectasis, and massive bleeding.[5,9] Thoracotomy is the most frequently used approach in hydatid cyst surgery, though the videothoracoscopic approach is becoming more common.[14–18] In our center, we usually prefer thoracotomy in patients with centrally located or deep-seated cysts. We use the video-assisted thoracoscopic approach with peripheral lesions. In the present study, we performed videothoracoscopic surgery in 68 patients (24%). Due to the size and location of the cysts, we performed lobectomy in 34 patients and segmentectomy in 2 patients.

The postoperative morbidity rate in patients with hydatid cysts varies between 3.5 and 20%, and the mortality rate is 0–2%.[10,12–15,17] Consistent with the literature, one patient in the present study died on postoperative day 90, while morbidity occurred in 29 patients (10.2%). The most common postoperative morbidity was PAL. OK-432 is used effectively in the literature to reduce prolonged air leakage.[19,20] However, the health insurance system in our country does not provide OK-432; for this reason, we use blood pleurodesis for PAL.

Dogru et al.[7] reported that smaller cysts regressed with albendazole therapy, and stated that small-diameter cysts can be managed with medical treatment. However, we prefer surgical treatment due to the risk of infection, anaphylaxis, and hemoptysis associated with rupture of pulmonary hydatid cyst.

Limitations

The retrospective design, the multiple surgeons involved, the underrepresentation of female patients, and

the heterogeneity of the surgical methods are potential sources of bias in this study.

Conclusion

In conclusion, giant hydatid cysts are more frequently observed in young adults. This can be explained by delayed onset of symptoms due to greater elasticity and compliance of the lungs in younger patients. Hydatid cyst surgery can be performed successfully using a videothoracoscopic approach without increased morbidity and mortality.

Disclosure Statement

The authors declare no conflicts of interest related to this article.

References

1) Usluer O, Ceylan KC, Kaya S, et al. Surgical management of pulmonary hydatid cysts: Is size an important prognostic indicator? Tex Heart Inst J 2010; **37**: 429–34.
2) Sayir F, Cobanoğlu U, Sehitoğulları A, et al. Our eight-year surgical experience in patients with pulmonary cyst hydatid. Int J Clin Exp Med 2012; **5**: 64–71.
3) Mirshemirani AR, Razavi S, Sadeghian S. Surgical treatment of pulmonary hydatid cyst in 72 children. Tanaffos 2009; **8**: 56–61.
4) Arroud M, Afifi MA, El Ghazi K, et al. Lung hydatic cysts in children: comparison study between giant and non-giant cysts. Pediatr Surg Int 2009; **25**: 37–40.
5) Dakak M, Caylak H, Kavakli K, et al. Parenchyma-saving surgical treatment of giant pulmonary hydatid cysts. Thorac Cardiovasc Surg 2009; **57**: 165–8.
6) Karaoglanoglu N, Kurkcuoglu IC, Gorguner M, et al. Giant hydatid lung cysts. Eur J Cardiothorac Surg 2001; **19**: 914–17.
7) Doğru D, Kiper N, Ozçelik U, et al. Medical treatment of pulmonary hydatid disease: for which child? Parasitol Int 2005; **54**: 135–8.
8) Arroud M, Afifi MA, El Ghazi K, et al. Lung hydatic cysts in children: comparison study between giant and non-giant cysts. Pediatr Surg Int 2009; **25**: 37–40.
9) Ramos G, Orduña A, García-Yuste M. Hydatid cyst of the lung: diagnosis and treatment. World J Surg 2001; **25**: 46–57.
10) Nachev P. Europe PMC Funders Group Europe PMC Funders Author Manuscripts. 2009; **19**:586–92.
11) Burgos R, Varela A, Castedo E, et al. Pulmonary hydatidosis: surgical treatment and follow-up of 240 cases. Eur J Cardiothorac Surg 1999; **16**: 628–34. discussion 634-5
12) Aribas OK, Kanat F, Turk E, et al. Comparison between pulmonary and hepatopulmonary hydatidosis. Eur J Cardiothorac Surg 2002; **21**: 489–96.
13) Erdogan A, Ayten A, Kabukcu H, et al. One-stage transthoracic operation for the treatment of right lung and liver hydatid cysts. World J Surg 2005; **29**: 1680–6.
14) Alpay L, Lacin T, Ocakcioglu I, et al. Is video-assisted thoracoscopic surgery adequate in treatment of pulmonary hydatidosis? Ann Thorac Surg 2015; **100**: 258–62.
15) Findikcioglu A, Karadayi S, Kilic D, et al. Video-assisted thoracoscopic surgery to treat hydatid disease of the thorax in adults: Is it feasible? J Laparoendosc Adv Surg Tech A 2012; **22**: 882–5.
16) Himuro N, Minakata T, Oshima Y, et al. Video-assisted thoracic surgery for primary myelolipoma of the posterior mediastinum. J Cardiothorac Surg 2016; **11**: 1.
17) Ocakcioglu I. Single-port thoracoscopic surgery for a hudge hydatid cyst. Gen Thorac Cardiovasc Surg 2017; **65**: 235–8.
18) Galetta D, Pelosi G, Nebuloni M, et al. Challenging diagnosis of an unusual solitary pulmonary nodule. Thorac Cardiovasc Surg 2007; **55**: 123–5.
19) How CH, Tsai TM, Kuo SW, et al. Chemical pleurodesis for prolonged postoperative air leak in primary spontaneous pneumothorax. J Formos Med Assoc 2014; **113**: 284–90.
20) Ogawa K, Takahashi Y, Murase K, et al. OK-432 pleurodesis for the treatment of pneumothorax in patients with interstitial pneumonia. Respir Investig 2018; **56**: 410–7.