Original Article – Pediatric Urology
Grand J Urol 2026;6(3):116-21
DOI: 10.5505/GJU.2026.60490

Uroflowmetry Findings and Their Association with Cystoscopic and Histopathological Features in Pediatric Idiopathic Urethritis

Pediatrik İdiyopatik Üretritte Üroflowmetri Bulguları ve Bunların Sistoskopik ve Histopatolojik Özelliklerle İlişkisi

Hasan Deliağa[1], Halil Tosun[2], Bilge Karabulut[3], Tuğrul Tiryaki[3]

[1]Department of Pediatric Urology, University of Health Sciences, Bursa Medical Faculty, Bursa, Türkiye
[2]Department of Pediatric Urology, Kayseri Erciyes University Medical Faculty, Kayseri, Türkiye
[3]Department of Pediatric Urology, University of Health Sciences, Ankara Bilkent City Hospital, Ankara, Türkiye

Cite as: Deliağa H, Tosun H, Karabulut B, Tiryaki T. Uroflowmetry findings and their association with cystoscopic and histopathological features in pediatric idiopathic urethritis. Grand J Urol 2026;6(3):116-21

Submission date: 05 June 2026 **Acceptance date:** 11 August 2026 **Online first:** 20 August 2026 **Publication date:** 21 September 2026

Corresponding Author: Hasan Deliağa / University of Health Sciences, Bursa Medical Faculty, Department of Pediatric Urology, Bursa, Türkiye
drhasandeliaga@hotmail.com / ORCID ID: 0000-0003-0567-3581

Abstract

Objective: To evaluate the association between uroflowmetry findings and cystoscopic and histopathological features in pediatric idiopathic urethritis (IU).
Materials and Methods: We retrospectively analyzed 87 pediatric patients with IU and available uroflowmetry data. Patients undergoing cystoscopy with biopsy represented a clinically selected subgroup with persistent, recurrent, or clinically more concerning symptoms during routine care. Uroflowmetry parameters and curve patterns were compared with those of conservatively managed patients. Histopathological findings, including squamous metaplasia and estrogen receptor expression, were reviewed qualitatively in biopsy specimens.
Results: Thirty patients (34.5%) underwent cystoscopy with biopsy and 57 (65.5%) were managed conservatively. The cystoscopy/biopsy subgroup had lower Qmax (median 9.4 vs. 18.8 mL/s, $p < 0.001$) and Qave (median 6.8 vs. 10.7 mL/s, $p < 0.001$). Plateau flow was more frequent in this subgroup (93.3% vs. 50.9%, $p < 0.001$). Exploratory ROC analysis showed an AUC of 0.88 for Qmax; however, the threshold is descriptive because cystoscopy selection was clinician-driven. Biopsy specimens demonstrated squamous metaplasia with estrogen receptor expression.
Conclusion: Abnormal uroflowmetry findings were associated with a clinically selected subgroup of pediatric IU patients who underwent cystoscopy/biopsy. Uroflowmetry may support non-invasive assessment and follow-up. Squamous metaplasia and estrogen receptor expression observed in selected biopsy specimens may represent possible biological correlates requiring prospective validation.
Keywords: idiopathic urethritis; uroflowmetry; cystoscopy; squamous metaplasia; estrogen receptor; pediatric urology

Özet

Amaç: Bu çalışmanın amacı, pediatrik idiyopatik üretritte (İÜ) üroflowmetri bulguları ile sistoskopik ve histopatolojik özellikler arasındaki ilişkiyi değerlendirmektir.
Gereçler ve Yöntemler: Üroflowmetri verileri mevcut olan 87 pediatrik İÜ hastası retrospektif olarak incelendi. Sistoskopi ve biyopsi uygulanan hastalar, rutin klinik uygulamada persistan, tekrarlayan veya klinik olarak daha dikkat çekici semptomları nedeniyle seçilmiş bir alt grubu temsil etmekteydi. Üroflowmetri parametreleri ve işeme eğrisi paternleri, konservatif olarak yönetilen hastalarla karşılaştırıldı. Biyopsi örneklerinde skuamöz metaplazi ve östrojen reseptör ekspresyonu dahil olmak üzere histopatolojik bulgular kalitatif olarak değerlendirildi.
Bulgular: Otuz hastaya (%34,5) sistoskopi ve biyopsi uygulanırken, 57 hasta (%65,5) konservatif olarak takip edildi. Sistoskopi/biyopsi grubunda maksimum akım hızı (Qmax) [medyan 9,4 mL/s'ye karşı 18,8 mL/s; $p < 0,001$] ve ortalama akım hızı (Qave) [medyan 6,8 mL/s'ye karşı 10,7 mL/s; $p < 0,001$] anlamlı olarak daha düşüktü. Plato tip akım paterni bu grupta daha sık gözlendi (%93,3'e karşı %50,9; $p < 0,001$). Keşifsel ROC analizinde Qmax için eğri altında kalan alan (AUC) 0,88 olarak bulundu; ancak sistoskopi kararı klinisyen tercihine dayandığından, belirlenen eşik değer yalnızca tanımlayıcı niteliktedir. Biyopsi örneklerinde östrojen reseptör ekspresyonu gösteren skuamöz metaplazi saptandı.
Sonuç: Anormal üroflowmetri bulguları, sistoskopi/biyopsi uygulanan seçilmiş pediatrik idiyopatik üretrit hastalarıyla ilişkili bulundu. Üroflowmetri, non-invaziv değerlendirme ve takipte yararlı bir araç olabilir. Seçilmiş biyopsi örneklerinde saptanan skuamöz metaplazi ve östrojen reseptör ekspresyonu olası biyolojik ilişkiler olarak değerlendirilmeli ve prospektif çalışmalarla doğrulanmalıdır.

Anahtar kelimeler: idiyopatik üretrit; üroflowmetri; sistoskopi; skuamöz metaplazi; östrojen reseptörü; pediatrik üroloji

ORCID ID: **H. Tosun** 0000-0002-0289-869X **B. Karabulut** 0000-0002-5113-7467 **T. Tiryaki** 0000-0002-9544-1137

This is an Open Access article distributed under the terms of the Creative Commons Attribution NonCommercial License 4.0 (http://creativecommons.org/licenses/by-nc/4.0) which permits unrestricted non-commercial re-use, distribution, and reproduction in any medium, provided the original work is properly cited.

Introduction

Idiopathic urethritis (IU) is an uncommon but recognized pediatric urological condition that typically presents with urethrorrhagia, dysuria, and intermittent hematuria in prepubertal and early pubertal boys [1-6]. Although generally considered benign and self-limiting, IU can cause considerable anxiety for patients and families and may lead to repeated consultations or invasive diagnostic procedures in selected cases [7,8]. Its etiology remains unclear, and current management is largely empirical [1,9].

Proposed mechanisms include infectious, inflammatory, anatomical, and functional factors. Most patients have negative urine cultures and no systemic signs of infection, while dysfunctional elimination, voiding disturbances, meatal stenosis, and previous procedures have been reported with inconsistent associations [8,9]. Because IU is defined mainly by exclusion, objective markers that better characterize disease severity would be clinically useful.

Uroflowmetry is a simple, non-invasive tool for assessing lower urinary tract function. Maximum flow rate (Qmax), average flow rate (Qave), voided volume, flow time, and curve pattern may reflect altered voiding dynamics or outlet obstruction. Although uroflowmetry is commonly used in other pediatric lower urinary tract conditions, its role in IU has not been well defined [10]. If epithelial or functional urethral changes contribute to IU, these changes may be reflected in uroflowmetry patterns.

Histopathological studies have reported squamous metaplasia in IU, suggesting a reactive epithelial process [4]. Estrogen-related mechanisms have also been proposed, as estrogen exposure can induce squamous metaplasia in male urogenital tissues and estrogen receptor expression has been identified in the male urethra [11,12]. The clinical relevance of these observations in pediatric IU remains uncertain.

The aim of this study was to evaluate the association between uroflowmetry parameters and cystoscopic and histopathological findings in pediatric IU. Patients undergoing cystoscopy and biopsy were considered a clinically selected subgroup with persistent or more severe symptoms during routine care, not an independently defined endpoint. We also explored histopathological findings, including squamous metaplasia and estrogen receptor expression, as potential biological correlates.

Materials and Methods

Study Design and Patients

This retrospective study included pediatric patients diagnosed with IU at participating institutions during the study period. Institutional ethics committee approval was obtained before data collection (Approval no: E-37732058-514.10), and the study was conducted in accordance with the Declaration of Helsinki.

Patients were identified through institutional databases and chart review. Inclusion criteria were presentation with urethrorrhagia, dysuria, and/or intermittent hematuria; absence of identifiable infectious, anatomical, or neurological causes after standard evaluation; and available uroflowmetry data. Patients with confirmed urinary tract infection, urethral stricture, prior urethral surgery other than minor procedures such as circumcision, neurological disorders affecting voiding, or incomplete records were excluded.

Clinical and Uroflowmetry Evaluation

Demographic data, presenting symptoms, symptom duration, and previous treatments were recorded. All patients underwent physical examination and urinalysis to exclude identifiable causes. Management decisions, including cystoscopy, were made by treating physicians according to routine clinical care, taking into account symptom severity, persistence or recurrence, response to conservative treatment, and overall clinical assessment. Cystoscopy with biopsy was performed in a clinically selected subgroup, generally because of persistent, recurrent, or clinically more concerning symptoms despite conservative management. No prospective standardized cystoscopy protocol was used; therefore, cystoscopy/biopsy status was analyzed as a clinical management subgroup rather than as an independently defined disease-severity endpoint.

Uroflowmetry was performed in toilet-trained patients according to institutional protocols when patients reported a normal desire to void. The dataset used for analysis contained one valid uroflowmetry recording per patient. Recorded variables were Qmax, Qave, voided volume, flow time, and curve pattern, categorized as normal, plateau, or staccato. Valid recordings were selected from technically adequate tracings with sufficient voided volume for clinical interpretation. Age-expected bladder capacity was calculated as (age + 2) x 30 mL and was used as a reference when assessing voided volume adequacy. Because of the retrospective design, repeated uroflowmetry was not standardized. Post-void residual urine was not consistently available in the retrospective dataset and was therefore not included in the analysis. Patients were grouped according to whether they underwent cystoscopy with biopsy during routine clinical management. This grouping was used for comparison only and was not intended to define an independent indication for cystoscopy.

Cystoscopy and Histopathology

Cystoscopy was performed in selected patients with persistent, recurrent, or clinically more concerning symptoms. The location and extent of urethral involvement were recorded. Biopsy specimens were fixed in formalin, embedded in paraffin, sectioned, and evaluated using hematoxylin and eosin staining. Squamous metaplasia was defined as replacement of the native urethral urothelium by squamous epithelium and was recorded qualitatively as present or absent. Estrogen receptor immunohistochemistry was assessed qualitatively according to the presence and distribution of nuclear staining in epithelial and stromal cells. Staining intensity and distribution were reported in descriptive terms rather than scored using a formal semi-quantitative system. Histopathological and immunohistochemical assessments were performed as part of routine institutional pathology evaluation; a centralized blinded multi-pathologist rereview was not performed.

Statistical Analysis

Statistical analysis was performed using SPSS version 27.0 (IBM Corp., Armonk, NY, USA). Continuous variables were

Table 1. Baseline characteristics of the study population

Variable	Cystoscopy/biopsy group (n=30)	Conservatively managed group (n=57)	P value
Age (years), median (IQR)	12.0 (11.0-13.8)	13.0 (11.0-15.0)	0.108
Dysuria duration (months), median (IQR)	12.0 (11.0-15.8)	14.0 (12.0-18.0)	0.085
Urethrorrhagia duration (days), median (IQR)	15.0 (10.0-25.0)	20.0 (15.0-30.0)	0.058

IQR: interquartile range

assessed for normality with the Shapiro-Wilk test and compared using the Mann-Whitney U test. Categorical variables, including flow curve pattern, were compared using the chi-square or Fisher exact test, as appropriate.

Receiver operating characteristic (ROC) analysis was performed exploratorily to assess the ability of Qmax to distinguish the clinically selected cystoscopy/biopsy subgroup from conservatively managed patients. Because cystoscopy was clinician-driven and not prospectively standardized, ROC-derived thresholds were interpreted as descriptive and hypothesis-generating rather than validated indications for cystoscopy. The identified Qmax threshold should therefore not be considered a standalone indication for cystoscopic evaluation. Area under the curve (AUC), sensitivity, specificity, positive predictive value (PPV), and negative predictive value (NPV) were calculated for the selected threshold. Logistic regression assessed the association of Qmax with cystoscopy/biopsy status after adjustment for age and voided volume. A p value <0.05 was considered statistically significant.

Results

A total of 87 patients met the inclusion criteria. Thirty patients (34.5%) underwent cystoscopy with biopsy as part of clinical management, and 57 (65.5%) were managed conservatively. Age, dysuria duration, and urethrorrhagia duration did not differ significantly between groups (p = 0.108, p = 0.085, and p = 0.058, respectively; **Table 1**).

Uroflowmetry parameters differed between groups **(Table 2)**. The cystoscopy/biopsy group had lower Qmax than the conservatively managed group (median 9.4 vs. 18.8 mL/s, p < 0.001) and lower Qave (median 6.8 vs. 10.7 mL/s, p < 0.001). Flow time was longer and voided volume was lower in the cystoscopy/biopsy group, but these differences did not reach statistical significance (p = 0.082 and p = 0.068, respectively).

Flow curve patterns were also associated with group status **(Table 3)**. A plateau pattern was present in 28 of 30 patients (93.3%) in the cystoscopy/biopsy group and 29 of 57 patients (50.9%) in the conservatively managed group. Normal flow curves were observed only in conservatively managed patients. Overall distribution differed significantly between groups (p < 0.001).

Exploratory ROC analysis showed good discrimination for Qmax in distinguishing the cystoscopy/biopsy subgroup from conservatively managed patients (AUC 0.88). A cutoff of approximately 10.6 mL/s provided sensitivity of 66.7%, specificity of 91.2%, PPV of 80.0%, and NPV of 83.9%. This threshold should be interpreted descriptively because endoscopic selection was not prospectively standardized **(Figure 1)**.

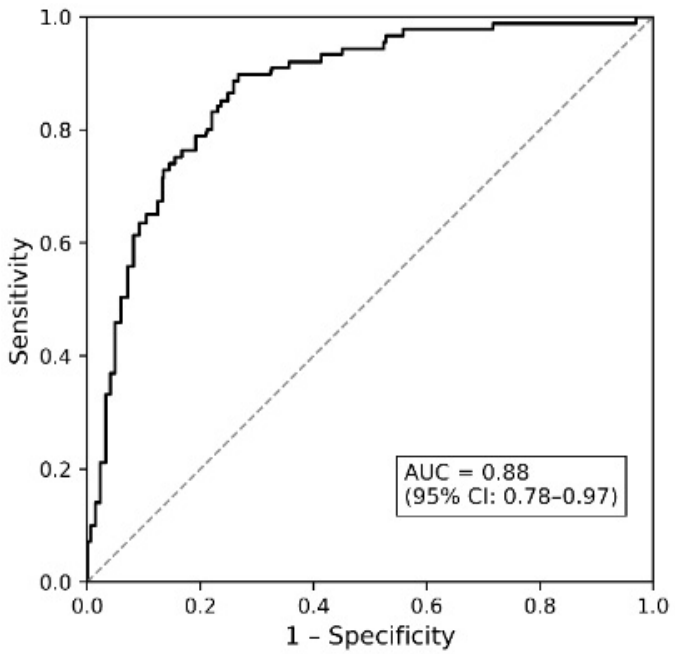

Figure 1. Receiver operating characteristic curve for Qmax distinguishing the clinically selected cystoscopy/biopsy subgroup from conservatively managed patients. AUC = 0.88 (95% CI: 0.78–0.97).

Table 2. Comparison of uroflowmetry parameters between groups

Parameter	Cystoscopy/biopsy group (n=30)	Conservatively managed group (n=57)	P value
Qmax (mL/s), median (IQR)	9.4 (7.0-14.6)	18.8 (14.8-25.0)	**<0.001**
Qave (mL/s), median (IQR)	6.8 (5.3-8.3)	10.7 (8.0-16.7)	**<0.001**
Flow time (s), median (IQR)	39.0 (30.5-49.5)	30.0 (21.0-45.0)	0.082
Voided volume (mL), median (IQR)	240.0 (171.8-358.5)	291.0 (191.0-556.0)	0.068

Values are median (IQR; 25th-75th percentile). Qmax:maximum flow rate; Qave: average flow rate

Table 3. Distribution of uroflow curve patterns

Curve pattern	Cystoscopy/biopsy group (n=30)	Conservatively managed group (n=57)
Normal	0 (0%)	19 (33.3%)
Plateau	28 (93.3%)	29 (50.9%)
Staccato	2 (6.7%)	9 (15.8%)

Percentages are presented within each group. Overall comparison $p < 0.001$

In logistic regression including Qmax, age, and voided volume, Qmax remained significantly associated with cystoscopy/biopsy status (OR 0.70, 95% CI 0.59-0.82, $p < 0.001$). This corresponds to an approximate 30% decrease in the odds of belonging to the cystoscopy/biopsy subgroup for each 1 mL/s increase in Qmax. Age and voided volume were not significantly associated with group status.

Cystoscopy demonstrated urethral involvement predominantly in the prostatic urethra, with extension to the bulbar or entire urethra in some patients. All available biopsy specimens from the cystoscopy group showed squamous metaplasia. Estrogen receptor immunohistochemistry demonstrated strong and diffuse expression in epithelial cells within metaplastic regions **(Figure 2)**.

Discussion

This study provides an integrated clinicopathological assessment of pediatric idiopathic urethritis (IU), combining non-invasive uroflowmetry with cystoscopic, histopathological, and immunohistochemical findings. The principal finding is that objective uroflowmetry abnormalities, particularly reduced Qmax, reduced Qave, and a plateau flow pattern, were strongly associated with the clinically selected subgroup that underwent cystoscopy and biopsy. In contrast, symptom duration did not differ significantly between groups, suggesting that clinical history alone may not adequately reflect functional severity in IU.

The magnitude of the uroflowmetry differences is clinically meaningful. Median Qmax was approximately two-fold lower in the cystoscopy/biopsy group than in conservatively managed patients [9.4 (7.0-14.6) vs. 18.8 (14.8-25.0) mL/s], and Qave showed a similar reduction [6.8 (5.3-8.3) vs. 10.7 (8.0-16.7) mL/s]. In addition, a plateau flow pattern was present in 93.3% of patients in the cystoscopy/biopsy group, whereas normal flow curves were observed only among conservatively managed patients. These findings suggest that abnormal uroflowmetry in IU is not merely a numerical variation, but may reflect altered urethral dynamics in a subgroup with more clinically significant disease.

This observation has practical clinical relevance. IU is generally considered benign and often self-limiting, but a subset of patients experience persistent urethrorrhagia, dysuria, or hematuria that leads to repeated consultations and uncertainty regarding further evaluation [1,2,9]. Uroflowmetry offers an objective, inexpensive, and non-invasive method to complement clinical assessment. In this context, normal flow parameters may support conservative management and reassurance, whereas reduced Qmax or a plateau pattern may identify patients who require closer follow-up and individualized consideration of further evaluation if symptoms persist.

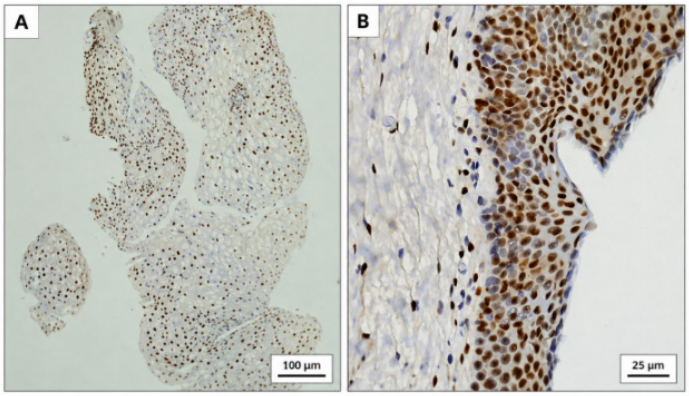

Figure 2. Estrogen receptor immunohistochemistry demonstrating nuclear expression in metaplastic urethral epithelium and stromal cells. (A) Low-power view showing diffuse nuclear ER expression in squamous metaplastic epithelium (×100 magnification). (B) High-power view demonstrating strong nuclear ER expression in both squamous epithelium and stromal cells (×400 magnification).

The regression and ROC findings strengthen this functional interpretation. Qmax remained significantly associated with cystoscopy/biopsy status after adjustment for age and voided volume, indicating that the observed association was not explained only by age-related flow differences or voiding volume. Exploratory ROC analysis showed good discrimination (AUC 0.88), and the proposed Qmax threshold of approximately 10.6 mL/s demonstrated high specificity. Because cystoscopy was clinically selected and not performed according to a prospective standardized protocol, this threshold should not be interpreted as a validated indication for invasive evaluation or as a standalone criterion for cystoscopy. Rather, it identifies a reproducible functional signal that may be useful for future prospective protocols with predefined criteria.

The histopathological findings provide a biologically plausible explanation for the uroflowmetry abnormalities. Squamous metaplasia was identified in all available biopsy specimens, consistent with previous reports describing epithelial remodeling in IU [1,4]. Such epithelial change may alter urethral compliance, luminal configuration, or local mucosal behavior, thereby contributing to the plateau curves and reduced flow rates observed in this cohort. This functional-pathological link is one of the central strengths of the present study: uroflowmetry abnormalities were not evaluated in isolation, but in relation to tissue-level changes in the affected urethra.

The estrogen receptor findings add a further translational dimension. Strong estrogen receptor expression in metaplastic urethral epithelium does not prove hormonal causality, but it supports the biological plausibility of hormone-responsive epithelial remodeling. Experimental data show that estrogen exposure can induce squamous metaplasia in male urogenital tissues, and estrogen receptor expression has been described in male urethral structures [11,12]. The typical occurrence of IU around puberty and its tendency toward eventual resolution are also compatible with a hormonally influenced process [13]. However, because healthy pediatric urethral control tissue was not available, estrogen receptor expression should be interpreted as a biological observation in selected biopsy specimens rather

than as a disease-specific feature. Similarly, the reported benefit of steroid instillation in some series may reflect not only anti-inflammatory activity but potentially modulation of epithelial or hormonal pathways [14-18]. These observations should be considered hypothesis-generating and warrant further biological study.

To our knowledge, this is among the few studies to evaluate pediatric IU through a combined functional, endoscopic, histopathological, and immunohistochemical framework. This integrated approach is important because IU has traditionally been defined by exclusion and managed empirically. By linking uroflowmetry patterns with cystoscopic and tissue findings, the present study shifts the discussion from symptom description alone toward a more structured model of disease phenotype. The findings do not advocate routine cystoscopy or biopsy in all patients; rather, they suggest that uroflowmetry can help characterize disease severity and support a more selective, individualized approach.

The study has limitations. Its retrospective design introduces selection bias, and cystoscopy was based on physician judgment, symptom persistence, clinical severity, and possibly uroflowmetry findings themselves. Therefore, cystoscopy/biopsy status should be interpreted as a marker of a clinically selected subgroup rather than as an independent disease-severity endpoint. In addition, conservatively managed patients did not undergo endoscopic or histological confirmation, control urethral tissue was unavailable, serum hormone levels were not measured, post-void residual urine was not consistently available, and uroflowmetry may be influenced by voided volume and patient cooperation. Because estrogen receptor expression was evaluated only in selected biopsy specimens, it cannot be considered disease-specific in the absence of control tissue. These limitations restrict causal interpretation, but they do not negate the observed association between abnormal uroflowmetry and the clinically more severe phenotype.

Future prospective studies should evaluate standardized uroflowmetry protocols, repeated or confirmatory uroflowmetry when appropriate, longitudinal symptom and flow outcomes, predefined criteria for cystoscopic evaluation, and quantitative histopathological or immunohistochemical assessment. Inclusion of appropriate control tissue, hormonal evaluation, post-void residual assessment, and longer follow-up would help clarify whether squamous metaplasia and estrogen receptor expression are causal features, adaptive responses, or markers of disease stage. Such studies may ultimately allow uroflowmetry to be incorporated into evidence-based follow-up strategies for pediatric IU.

Conclusion

Abnormal uroflowmetry findings were associated with a clinically selected subgroup of pediatric IU patients who underwent cystoscopic evaluation. These patients had significantly lower flow rates and a higher prevalence of plateau flow patterns than conservatively managed patients.

Squamous metaplasia and estrogen receptor expression observed in biopsy specimens may represent possible biological correlates of pediatric IU, but they should not be interpreted as direct evidence of pathogenesis without prospective validation and appropriate control tissue. Uroflowmetry should be viewed as a non-invasive adjunct to clinical assessment and follow-up, not as a standalone indication for invasive evaluation. Prospective studies using standardized uroflowmetry protocols, predefined cystoscopy criteria, control tissues, hormonal assessment, post-void residual assessment, and longitudinal follow-up are needed to validate these findings.

Ethics Committee Approval: This study was approved by the Non-Interventional Clinical Research Ethics Committee of Erzurum Regional Training and Research Hospital (Decision Date:02.08.2021, Approval no: E-37732058-514.10).
Informed Consent: Written informed consent was obtained from all patients and their parents.
Publication: The results of the study were not published in full or in part in form of abstracts.
Peer-review: Externally peer-reviewed.
Authorship Contributions: Any contribution was not made by any individual not listed as an author. Concept – H.D.; Design – H.D.; Supervision – H.D., B.K., T.T.; Resources – H.D., H.T.; Materials – H.D.; Data Collection and/or Processing – H.D., H.T.; Analysis and/or Interpretation – H.D.; Literature Search – H.D., H.T.; Writing Manuscript – H.D.; Critical Review – H.D., B.K., T.T.
Conflict of Interest: The authors declare that they have no conflicts of interest.
Financial Disclosure: The authors declare that this study received no financial support.

References

[1] Eyer de Jesus L, Fazecas T, Anderson KM, Dekermacher S. Idiopathic hemorrhagic urethritis of childhood. J Pediatr Urol. 2020;16(5):690–9. https://doi.org/10.1016/j.jpurol.2020.07.021

[2] Henderson L, Farrelly P, Dickson AP, Goyal A. Management strategies for idiopathic urethritis. J Pediatr Urol. 2016;12(1):35.e1–5. https://doi.org/10.1016/j.jpurol.2015.07.002

[3] Van Howe RS, Cold CJ. Etiology of idiopathic anterior urethritis. Urology. 1999;53(3):658. https://pubmed.ncbi.nlm.nih.gov/10096405/

[4] Docimo SG, Silver RI, Gonzalez R, Muller SC, Jeffs RD. Idiopathic anterior urethritis in prepubertal and pubertal boys: pathology and clues to etiology. Urology. 1998;51(1):99–102. https://doi.org/10.1016/s0090-4295(97)00474-3

[5] Harrison SCW, Whitaker RH. Idiopathic urethritis in male children. Br J Urol. 1987;59(3):258–60. https://doi.org/10.1111/j.1464-410x.1987.tb04618.x

[6] Cartwright PC. Urethrorrhagia. In: Rabinowitz R, Hulbert WC, Mevorach RA, editors. Pediatric urology for the primary care physician. New York: Humana Press; 2014. p. 221–4.

[7] Williams DI, Mikhael BR. Urethritis in male children. Proc R Soc Med. 1971;64(2):133–4. https://pubmed.ncbi.nlm.nih.gov/5548923/

[8] Herz D, Weiser A, Collette T, Reda E, Levitt S, Franco I. Dysfunctional elimination syndrome as an etiology of idiopathic urethritis in childhood. J Urol. 2005;173(6):2132–7. https://doi.org/10.1097/01.ju.0000157686.28359.c7

[9] Degheili JA, Dickson AP. Childhood and adolescent idiopathic urethritis: what does the current literature say? J Pediatr Urol. 2020;16(3):276–83. https://doi.org/10.1016/j.jpurol.2020.02.001

[10] Alyami F, Farhat W, Figueroa VH, Romao RLP. Utility and cost-effectiveness of uroflowmetry in a busy pediatric urology practice. Can Urol Assoc J. 2014;8(9-10):e615–8. https://doi.org/10.5489/cuaj.2190

[11] Zuckerman S. The histogenesis of tissues sensitive to oestrogens. Biol Rev Camb Philos Soc. 1940;15(2):231–70.

[12] Cooke PS, Young P, Hess RA, Cunha GR. Estrogen receptor expression in the developing epididymis, efferent ductules and other male reproductive organs. Endocrinology. 1991;128(6):2874–9. https://doi.org/10.1210/endo-128-6-2874

[13] Klein KO, Martha PM, Blizzard RM, Herbst T, Rogol AD. A longitudinal assessment of hormonal and physical alterations during normal puberty in boys II. Estrogen levels as determined by an ultrasensitive bioassay. J Clin Endocrinol Metab. 1996;81(9):3203–7. https://doi.org/10.1210/jcem.81.9.8784070

[14] Ashraf J, Radford AR, Turner A, Subramaniam R. Preliminary experience with instillation of triamcinolone acetonide into the urethra for idiopathic urethritis: a prospective pilot study. J Laparoendosc Adv Surg Tech A. 2017;27(11):1217-1221. https://doi.org/10.1089/lap.2017.0064

[15] Jayakumar S, Ninan GK, Pringle K. Steroid instillation for idiopathic urethritis in children: an 8 year experience. Eur J Pediatr Surg. 2015;25(2):212–5. https://doi.org/10.1055/s-0034-1368800

[16] Eradi B, Ninan K. Intravesical steroid instillation-a novel therapeutic intervention for idiopathic urethritis of childhood. Eur J Pediatr Surg. 2009;19(2):105–7. https://doi.org/10.1055/s-2008-1039193

[17] Eyster KM. The estrogen receptors: an overview from different perspectives. In: Eyster KM, editor. Estrogen receptors: methods and protocols. New York: Springer; 2016. p. 1–10.

[18] Gong H, Jarzynka MJ, Cole TJ, Lee JH, Wada T. Glucocorticoids antagonize estrogens by glucocorticoid receptor mediated activation of estrogen sulfotransferase. Cancer Res. 2008;68(18):7386–93. https://doi.org/10.1158/0008-5472.CAN-08-1545